

case review

mild procedure

Sanghamitra Basu, MD

North Vista Hospital

Las Vegas, Nevada

Performed January 8, 2010

patient information:

-51 year old male

pre-mild procedure:

-Reported 10/10 on VAS Score

-Pain Description & Activity Level: Patient had a history of low back pain, radiated down his legs. MRI revealed history of DDD and spinal stenosis with ligamentum flavum hypertrophy. Subject had tried all conservative care, including physical therapy and medications. He was having trouble sitting and standing while performing daily activities. Patient was unable to get out of bed without rolling to the bed's edge first and sitting on the bed for approximately 15 minutes prior to standing.

mild procedure information:

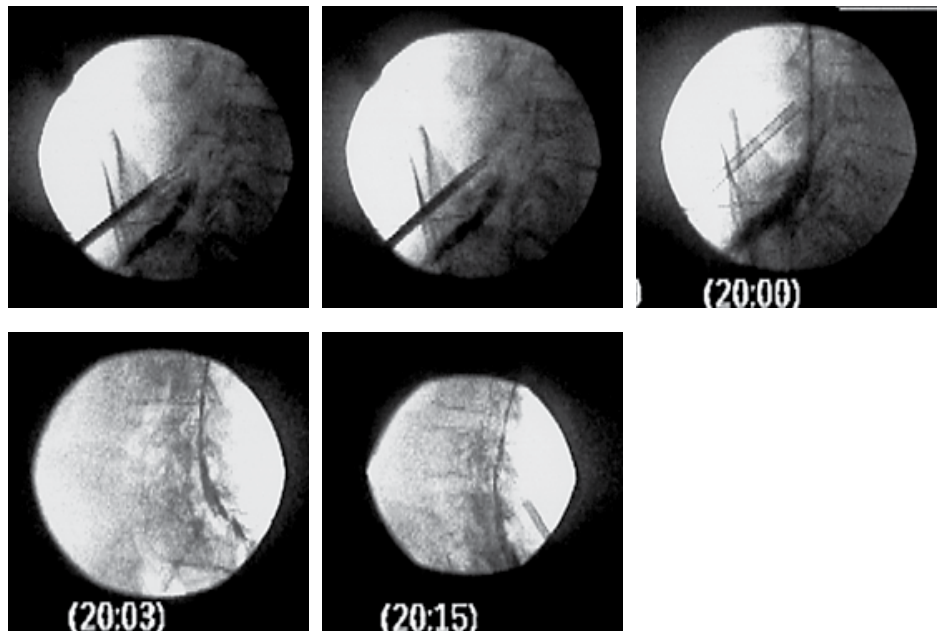
-Levels Treated: L3-L4 and L4-L5

-Type of Anesthesia: Local with MAC

post-mild information:

-Reported 0/10 on VAS Score

-Pain Description & Activity Level: At one week, patient no longer complained of lower back pain or radiating bilateral leg pain. Subject has no limits sitting and standing as well as walking any distances. Upon rising in the morning, his wife noticed that he no longer sits at edge of bed before getting up. Subject "pops up" from the bed and proceeds straight to washroom, starting the morning, "quickly".



For more information,
please contact
Doug Heidrich
602.330.9509

Headquarters/Training Center
11 Columbia, Suite B, Aliso Viejo, CA 92656
T: 877.958.6227 | F: 949.349.0218
www.Vertosmed.com

Vertos | *mild*
MEDICAL™ | Minimally Invasive
Lumbar Decompression